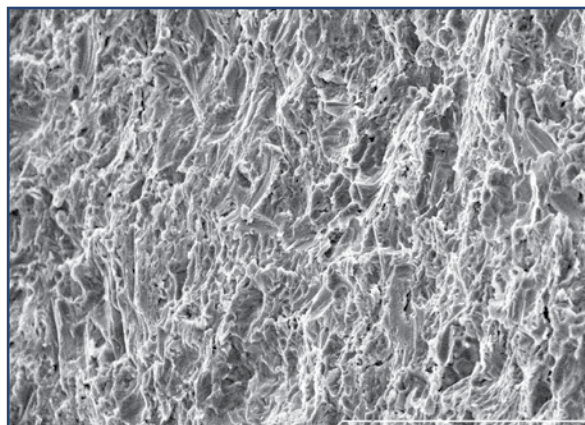


Long Term Clinical Survival of Two Tissue Level Implant Systems With Different Surface Modifications: A Retrospective Comparison With up to Five-Year Results

Emil M. Verban, Jr, DDS¹ • Asher S. Gelman, DMD²

Abstract



Purpose: The objective of this retrospective study was to compare the survival rate of two macroscopically similar tissue level dental implants with different surface modifications.

Materials and Methods: 124 patients received 247 implants placed between December 2005 and June 2008. Implants were either Straumann[®] Standard Plus (Straumann[®] AG, Basel, Switzerland) with SLA[®] surface modification (ST, n=133) or Blue Sky Bio[®] (Blue Sky Bio[®], LLC, Grayslake, USA) with resorbable blast media surface modification (BL, n=114) and were either placed immediately (IM, n=95,

[STIM n=43, BLIM n=52]) into fresh extraction sockets or following a delayed protocol (DE n=152 [STDE n=90, BLDE n=62]). Implants were followed for up to five years for survival.

Results: The survival rates of the compared groups were similar: 96.9% for group ST vs. 97.3% for group BL; 95.2% for STIM vs. 98.0% for BLIM; 97.3% for STDE vs. 96.7% for BLDE.

Conclusion: No statistically significant difference in long term survival of implants was observed between the compared groups. Both implants have predictable clinical survival rates.

KEY WORDS: Dental implants, implant survival, retrospective analysis

1. Private practice Bloomington, Illinois, USA
2. Private practice, Chicago, Illinois, USA




Figure 1: Scanning electron micrograph of SLA® surface.

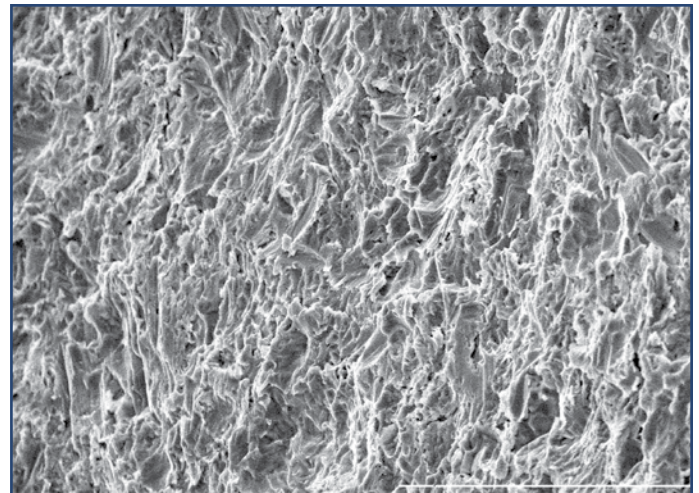


Figure 2: Scanning electron micrograph of RBM surface.

INTRODUCTION

Implant designs have been developed with variations in macroscopic topography and surface modification in order to improve biomechanical properties.^{1,2} Tissue level implants are designed with a trans-gingival collar to facilitate trans-gingival healing and a single stage surgical protocol.³ This protocol decreases the number of procedures, improves patient comfort and results in bone levels, success and survival rates similar to a two-stage protocol.^{4,5} Success has been attributed to a design that places the abutment/implant platform micro-gap coronal to the alveolar crest, in order to avoid bacterial insult and respects biologic width.⁶⁻⁹ Both tissue-level implant systems studied feature cylindrical body, 8-degree Morse-type tapered, internal octagon connection, smooth trans-gingival cervical portion, 45-degree shoulder, and surgical and prosthetic compatibility. Though macroscopically similar, each employs a unique surface modification (Figures 1,2).

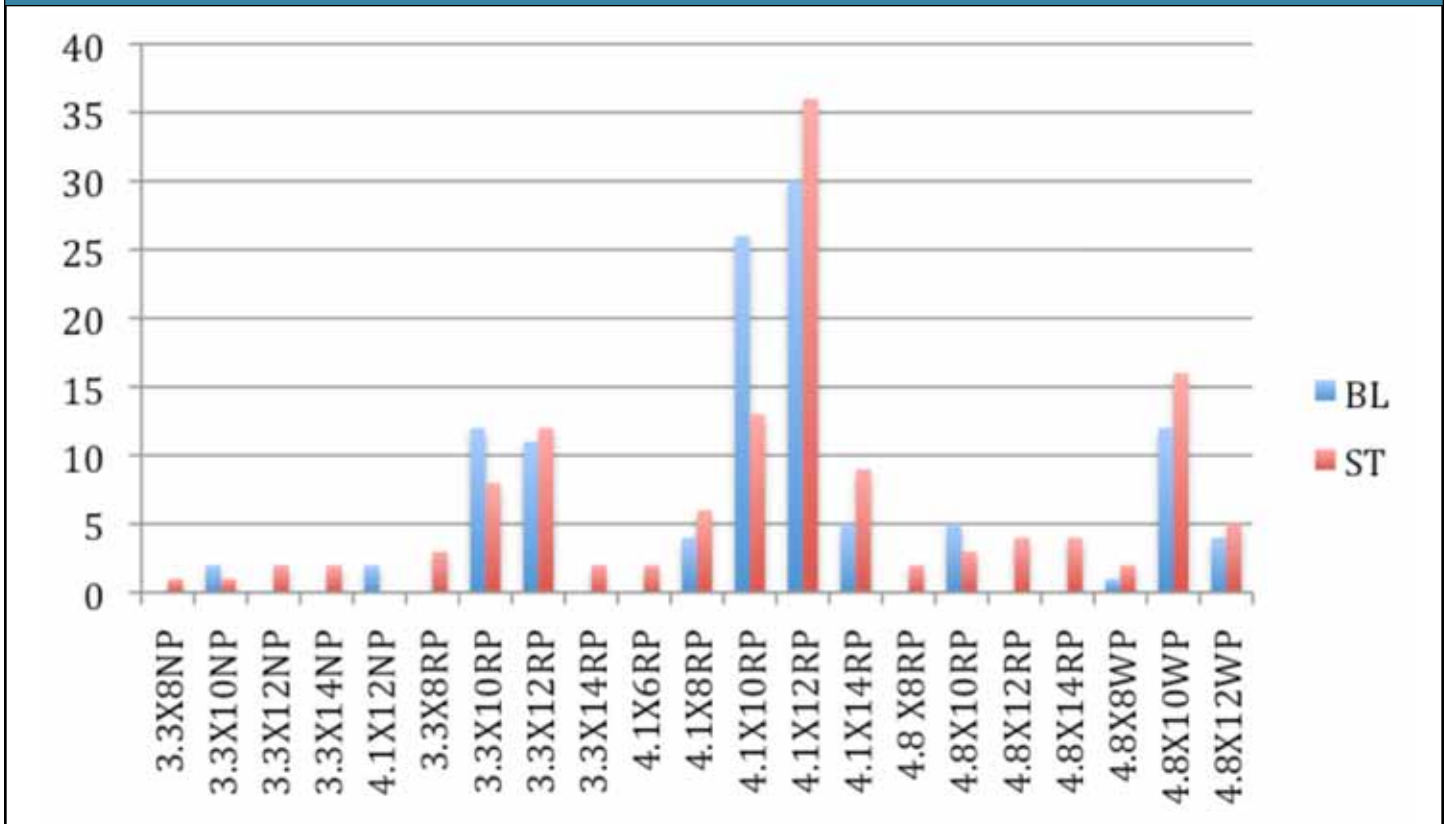
The Straumann® implant features a sand blasted large grit acid etched surface modi-

fication (SLA®). According to the manufacturer, the titanium surface is blasted with corundum particles to create macro-roughness and is then etched in a bath of heated HCl/H₂SO₄ acid solution to create micropits free of enclosed porosities.¹⁰ The surface modification produces a high bone to implant contact and high removal torque values.^{11,12}

The Blue Sky Bio® implant features a resorbable blast media surface treatment. The titanium implant surface is blasted with tricalcium phosphate and hydroxyapatite and then washed in nitric acid solution to remove all residue of blasting material.¹³ The process results in a predictable roughness without application of high temperatures and without introducing any foreign materials that may become embedded in the implants.^{13,14} Literature suggests that this surface promotes significantly more bone implant contact than machined surfaces, and promotes more bone apposition than surfaces blasted with nonresorbable bioceramics.^{15,16}

This retrospective study compared the clini-

Graph 1: Implant Size Distribution



cal survival rate of these two similarly designed tissue level implants. The similarity of the macroscopic topography and surgical protocol of the two systems offers an opportunity to compare the effect of the different surface modification.

METHODS

Records of all patients who had implants placed between December 5, 2005 and June 11, 2008 were evaluated. The implants were placed and restored by one clinician in a single private practice setting. A total of 124 patients were evaluated. All patients treated during that period were included in this study.

Patients were screened for medical and dental contraindications to implant placement by submitting to a medical questionnaire and completing medical and dental interview. Patients with incomplete jaw growth or reported history of intravenous bisphosphonate therapy, radiation therapy to the jaw, uncontrolled diabetes, severe metabolic bone disorders, uncontrolled systemic disease and metastatic cancer with involvement of bone were categorically excluded from treatment. In addition, other patients with chronic complex medical, emotional and psychological conditions were excluded either based on the judgment of the dentist or the consulting physician. Patients

Table 1: Implant Surgical Protocol and Location		
Surgical Protocol	ST	BL
Immediate Placement	43	52
Delayed Placement	90	62
Implant Location	ST	BL
Anterior Maxilla	35	23
Posterior Maxilla	47	46
Anterior Mandible	11	19
Posterior Mandible	40	26

Table 2: Implant Failure/Survival Summary		
	BL	ST
IM	1	2
DE	2	2
Total Failures	3	4
Total Loss to Recall	1 (IM)	1 (IM)
% Survival IM (based on recalled patients only)	98.0	95.2
% Survival DE	96.7	97.3
Cumulataive % Survival (based on recalled patients)	97.3	96.9

had to exhibit good oral hygiene and commitment to regular dental follow-up. Written informed consent was obtained from all patients.

Dental evaluation consisted of comprehen-

sive hard and soft tissue exam. When appropriate, mounted diagnostic models were used to evaluate inter and intra arch restorative space and occlusion. Implant sites were evaluated for

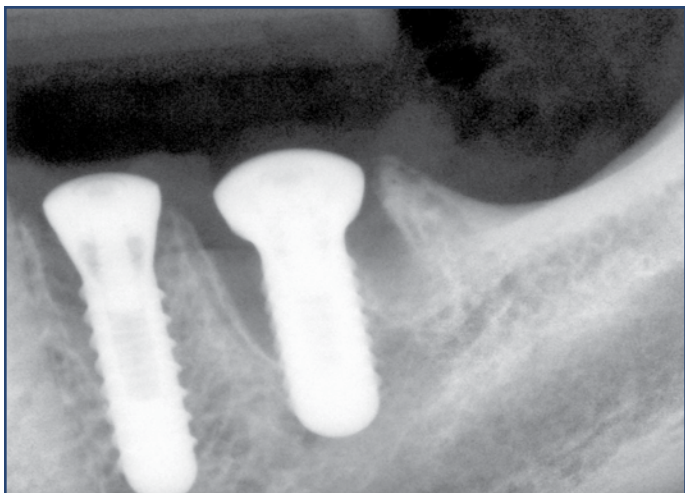


Figure 3: Blue Sky Bio® implants at time of immediate surgical placement.

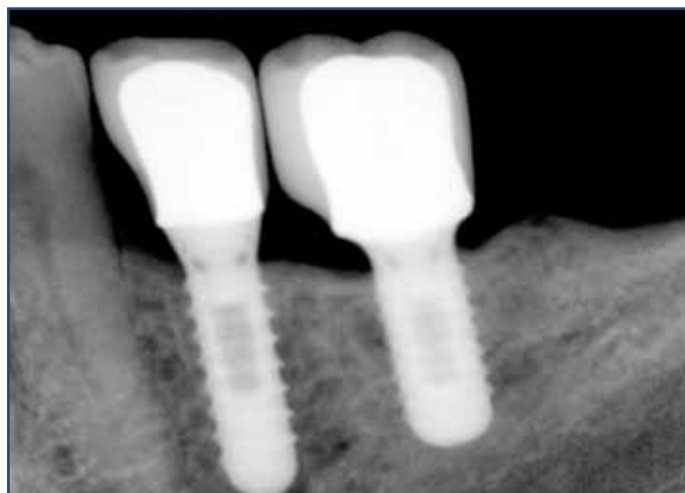

Figure 4: Blue Sky Bio® radiograph at 11 months post-op.

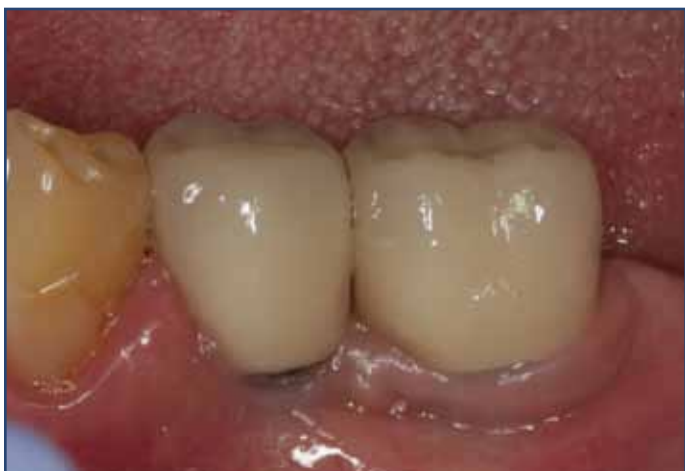

Figure 5: Photo of Blue Sky Bio® restorations at 11 months post-op.

adequate bone width and height with periapical and panoramic radiographs, digital palpation and/or bone mapping. For implants placed into fresh extraction sites, visual and tactile inspection of extraction sockets provided more information.

A total of 247 tissue-level dental implants were placed in the reviewed period. Implant diameters and lengths varied based on site and prosthetic considerations. (Implant size distribution is sum-

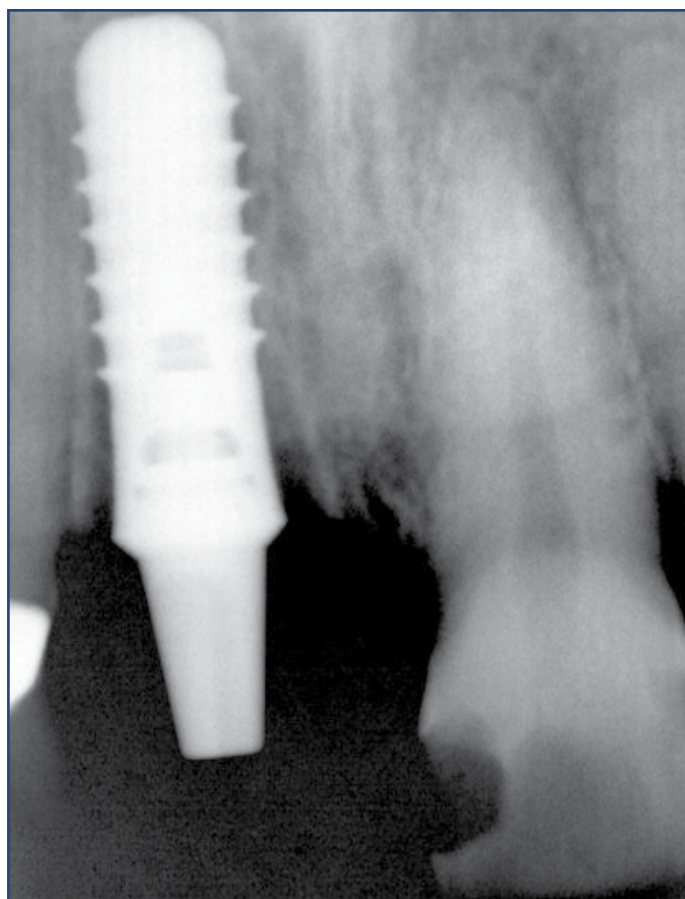


Figure 6: Straumann® implant at time of immediate surgical placement.

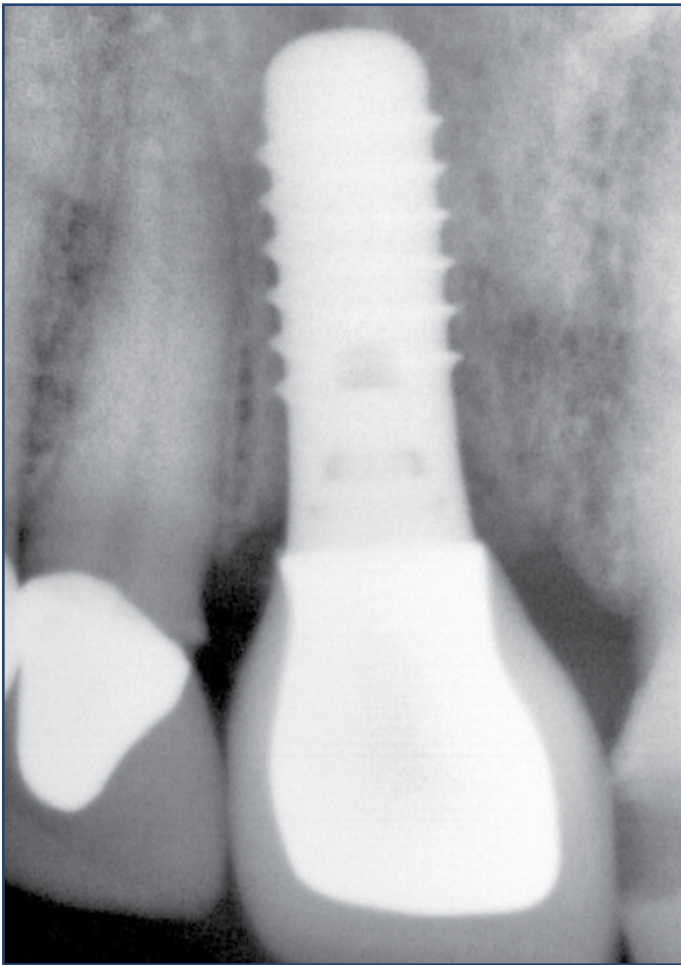


Figure 7: Straumann® implant at 18 months post-op.

marized in Graph 1). Of these, 133 were Straumann® Standard Plus SLA® and 114 were Blue Sky Bio® One Stage resorbable blast media. Of the Straumann®, 43 were placed into fresh extraction sites and 90 were placed into healed edentulous sites. Of the Blue Sky Bio® group, 52 were placed into fresh extraction sites at the time of extraction and 62 into healed edentulous sites. Implant site location, and placement protocol is summarized in Table 2. Straumann® instrumentation was used for both groups following the manufacturer's recommendations when possible. This was possible because Blue Sky Bio® implants are

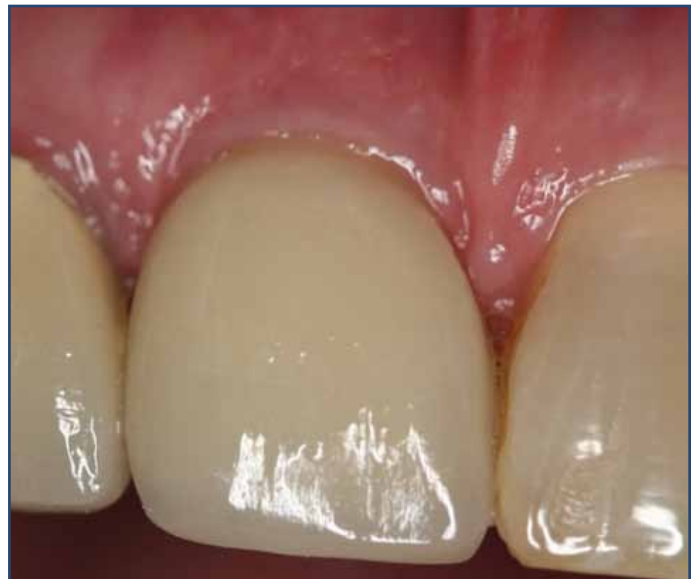

Figure 8: Photo of Straumann® restoration at 18 months post-op.

designed to be surgically compatible with Straumann® instrumentation. Surgery was performed under sterile conditions and site appropriate local anesthesia was administered. All implants were placed with a one-stage protocol with a healing abutment or immediate provisional restoration to avoid second stage surgery to uncover implants. Permanent restorations were placed after a healing period ranging from 10 weeks to 54 weeks.

Patients were seen for follow-up evaluations at approximately 1 week, 3 weeks, 2 months, when abutments were torqued for final restoration, and at periodic dental recall appointments thereafter. Abutments for final restorations were torqued according to manufacturer's recommended torque between 0 and 52 weeks. Prior to final restoration, implant integration was manually evaluated with percussion and palpation, visual inspection and radiographic appearance (Figures 3-8). Clinical survival was defined as absence of mobility upon manual testing, and applica-

tion of restorative torque as well as absence of mechanical failure of implants and irresolvable clinical symptoms, such as pain, discomfort, numbness, infection, or peri-implant bone loss.

RESULTS

Of the 247 implants placed, there were a total of 7 failures: 4 Straumann[®], and 3 Blue Sky Bio[®]. Two of the failed Straumann[®] implants were placed immediately one of which was also provisionally restored at time of placement. One of the failed Blue Sky Bio[®] implants was placed immediately and was also provisionally restored at time of placement. The survival rates of the compared groups were statistically similar: 96.9% for group Straumann[®] vs. 97.3% for group Blue Sky Bio[®]; 95.2% for Straumann[®] Immediate vs. 98.0% for Blue Sky Bio[®] Immediate; 97.3% for Straumann[®] Delayed vs. 96.7% for Blue Sky Bio[®] Delayed. Survival data is summarized in Table 2.

CONCLUSION

Within the observation period and the limitations of the parameters “implant survival,” no clinically relevant differences were observed between implants possessing a surface modification created by blasting with corundum particles followed by acid etching and those with a surface roughness produced by blasting with resorbable media particles followed by an acid wash. ●

Correspondence:

Dr. Emil M. Verban, Jr.
McLean County Dental
2103 E. Washington St.
Bloomington, IL 61701, USA
Phone: 309-662-8448

Disclosure: The authors report no conflicts of interest with anything mentioned in this article.

References:

1. Jones AA, Cochran DL. Consequences of implant design. *Dent Clin North Am.* 2006 Jul;50(3):339-60
2. Abrahamsson I, Berglund T. Effects of different implant surfaces and designs on marginal bone-level alterations: a review. *Clin Oral Implants Res.* 2009 Sep;20 Suppl 4:207-15.
3. Buser D, Belser UC, Lang NP. The original one-stage dental implant system and its clinical application. *Periodontol* 2000. 1998 Jun;17:106-18.
4. Weber HP, Buser D, Fiorellini JP, Williams RC. Radiographic evaluation of crestal bone levels adjacent to nonsubmerged titanium implants. *Clin Oral Implants Res.* 1992 Dec;3(4):181-8.
5. Reijden WA, Van Winkelhoff AJ, Stegenga B. Two-part implants inserted in a one-stage or a two-stage procedure: a prospective comparative study. *J Clin Periodontol* 2002;29(10):901-9.
6. Hermann JS, Cochran DL, Nummikoski PV, Buser D. Crestal bone changes around titanium implants. A radiographic evaluation of unloaded nonsubmerged and submerged implants in the canine mandible. *J Periodontol.* 1997 Nov;68(11):1117-30.
7. Hermann JS, Buser D, Schenk RK, Cochran DL. Crestal bone changes around titanium implants. A histometric evaluation of unloaded non-submerged and submerged implants in the canine mandible. *J Periodontol.* 2000 Sep;71(9):1412-24.
8. Weber HP, Buser D, Donath K, Fiorellini JP, Doppalapudi V, Paquette DW, Williams RC. Comparison of healed tissues adjacent to submerged and non-submerged unloaded titanium dental implants. A histometric study in beagle dogs. *Clin Oral Implants Res.* 1996 Mar;7(1):11-9.
9. Gross M, Abramovich I, Weiss EI. Microleakage at the abutment-implant interface of osseointegrated implants: a comparative study. *Int J Oral Maxillofac Implants.* 1999 Jan-Feb;14(1):94-100.
10. The Straumann SLA[®] Implant Surface: Clinically Proven Reduced Healing Time Available at: http://www.straumann.us/pc_15x_526_sla_healing_time.pdf Accessed March 22, 2011.
11. Cochran DL, Schenk RK, Lussi A, Higginbottom FL, Buser D. Bone response to unloaded and loaded titanium implants with a sand-blasted and acid-etched surface: A histometric study in the canine mandible. *J Biomed Mater Res* 1998;40:1-11.
12. Buser D, Nydegger T, Oxland T, Cochran DL, Schenk RK, Hirt HP, Snétivy D, Nolte L-P. Interface shear strength of titanium implants with a sandblasted and acid-etched surface: a bio-mechanical study in the maxilla of miniature pigs. *J Biomed Mater Res* 1999;45:75-83.
13. Blue Sky Bio Surface Available at: <https://www.blueskybio.com/category.php?cat=1040> accessed March 21, 2011.
14. Sanz A, Oyarzún A, Farias D, Diaz I. Experimental study of bone response to a new surface treatment of endosseous titanium implants. *Implant Dent.* 2001;10(2):126-31.
15. Novaes AB Jr, Souza SL, de Oliveira PT, Souza AM. Histomorphometric analysis of the bone-implant contact obtained with 4 different implant surface treatments placed side by side in the dog mandible. *Int J Oral Maxillofac Implants.* 2002 May-Jun;17(3):377-83.
16. Müller WD, Gross U, Fritz T, Voigt C, Fischer P, Berger G, Rogaschewski S, Lange KP. Evaluation of the interface between bone and titanium surfaces being blasted by aluminium oxide or bioceramic particles. *Clin Oral Implants Res.* 2003 Jun;14(3):349-56.