

Evaluation of palatal bone depth, cortical bone, and mucosa thickness for optimal orthodontic miniscrew placement performed according to the third palatal ruga clinical reference

Riccardo Nucera¹, Stefania Costa¹, Angela Mirea Bellocchio¹, Serena Barbera¹, Sara Drago², Armando Silvestrini², and Marco Migliorati²

¹Department of Biomedical and Dental Sciences and Morphofunctional Imaging, Section of Orthodontics, School of Dentistry, University of Messina, Italy

²Orthodontics Department, School of Dentistry, University of Genova, Italy

Correspondence to: Riccardo Nucera, AOU Policlinico 'G. Martino', UOC di Odontoiatria e Odontostomatologia, Via Consolare Valeria, 1, 98100 Messina, Italy.
E-mail: riccardo.nucera@gmail.com

Summary

Objectives: This retrospective CBCT study aimed to evaluate the palatal anatomical characteristics using the third palatal ruga as a reliable clinical reference for miniscrew placement.

Methods: Thirty-six subjects (mean age 17.1 y.o. ± 4.1) were randomly selected and their records (CBCT volume and maxillary digital models) were included.

BlueSkyPlan CBCT software viewer (BluSkyBio, V4.7) was used to measure the following outcomes at the level of third palatal ruga, 2 mm anteriorly and 2 mm posteriorly: total bone depth, cortical bone thickness, and mucosa thickness. The outcomes were evaluated on lines perpendicular to the palatal mucosa laying on different sagittal planes: the mid-palatal plane, 2 and 4 mm paramedian planes.

Results: The maximum mean amount of bone depth was registered 2 mm posteriorly to the third ruga and 4 mm paramedian (9.7 mm). No significant difference was observed between the third ruga insertion site and its corresponding 2 mm posterior site. Cortical bone of palatal vault did not change significantly in anteroposterior direction for all the considered sites. Significant differences were found comparing cortical bone at the suture level with cortical bone 2-mm and 4-mm paramedian at all anteroposterior levels. Palatal mucosa increases its thickness in paramedian insertion sites, and it decreases in posterior insertion sites.

Conclusions: Both third palatal ruga and 2 mm posteriorly to third ruga (4 mm paramedian) could be the optimal insertion site for palatal miniscrew placement, depending on individual anatomic conditions. The thickness of the cortical palatal bone showed, at 4 mm paramedian, optimal characteristics for miniscrew primary stability. Palatal mucosa thickness values suggest miniscrew neck extension of 2.0–2.5 mm for optimal mucosa adaptation.

Introduction

Miniscrew application in the palatal process of maxillary bone was proposed by different authors (1, 2). It offers several clinical advantages in many clinical conditions (1, 3, 4).

Several CBCT studies evaluated the bone thickness of the palatal vault, to investigate what are the best available insertion sites for skeletal anchorage. Among these, two CBCT studies used dental landmarks as clinical references to construct a grid for palatal bone thickness evaluation of different insertion sites (5, 6). Both these studies found a greater amount of palatal bone thickness at the anteroposterior level of the contact point between canine and premolar in the paramedian zone (5, 6). However, the anteroposterior position of interdental contact points used (5, 6) as clinical reference could show significant variability in several malocclusions (dental class II, missing lateral incisor, impacted canine, palatal/vestibular dental eruptions), producing potential evaluation bias.

Some authors suggested the palatal rugae remain stable over time (7, 8). They can be useful to evaluate growth (9), occlusion development, (9) and orthodontic treatment effects (10, 11).

The third palatal ruga was also proposed as a reference anatomical structure for miniscrew insertion (12). However, to the best of our knowledge, no study has been reported using palatal rugae as a direct clinical reference for palatal anatomical characteristics evaluation.

The purpose of this retrospective cross-sectional CBCT study is to evaluate bone and mucosal characteristics of the palatal vault in the region of the third palatal ruga, using this anatomical structure as a direct and reliable clinical reference for miniscrew placement.

Materials and methods

This retrospective cross-sectional CBCT study was reviewed and approved by the Ethics Committee of Genova (prot.

357/2018). It was conducted according to the principles of the Declaration of Helsinki.

The clinical archive of the university clinic was searched and the pre-treatment records of patients showing the following criteria were selected:

caucasian subjects with permanent dentition (excluding third molars) that performed a CBCT exam for unilateral eruption problems (such as impacted canine or impacted premolar), aged between 11 and 25 y.o.; absence of craniofacial abnormalities or congenital syndromes such as cleft lip and palate, cysts, or maxillary tumours; subjects including in their folder the following records: plaster models, CBCT of maxilla stored as DICOM file; no history of orthodontic treatment.

Sixty-four patients (35 females, 29 males) fulfilled the inclusion criteria, and their records were checked for quality and integrity. Patients were divided by sex into two numbered groups and every group was ordered by age. A random sequence generator was used to create lists of randomized numbers sequence of 35 and 29 numbers.

To set the sample size, a power analysis was carried out based on published data (5) reporting bone depth evaluation of the palatal insertion site approximately at the level of the third palatal ruga.

The considered data were: 4.5 mm, 2.68 mm, 2.44 mm (as common standard deviation). The power level has been set to 0.8 and the significance level to 5%. The results of the power analysis showed that a sample of 26 cases was necessary to obtain suitable data power. To exclude any risk of false-negative results it was decided to increase the sample size to 36 cases.

The first 18 numbers of both previously mentioned randomized lists were selected, and the corresponding patient's records were included. By this procedure, enrolment was performed in a balanced randomization scheme according to patient sex.

The final sample included 18 male subjects (mean age 17.3 y.o. \pm 3.9) and 18 female subjects (mean age 16.9 y.o. \pm 4.5). A previous study (13) reported no significant differences in total bone thickness outcome between male and female subjects and between subjects in late mixed and permanent dentition (13). Consequently, the study was designed to exclude sex and dentition development comparisons.

CBCT records were generated by i-CAT CBCT scanner (Imaging Sciences International, Hatfield, Pa), setting the following parameters acquisition: 120 kV, 5 to 8 mA, and 6 to 9 second exposure time. CBCT exams were exported (in DICOM format), anonymized and then imported in BlueSkyPlan software (BlueSkyBio LLC, V4.7-64 bit, Libertyville, IL, USA). CBCT exams import was executed re-orienting the palatal plane parallel to the axial plane. Upper arches of plaster models were digitalized with an extra-oral scanner (Maestro 3D, Age Solutions, Pisa, Italy) and exported in STL (STereoLithography) File Format. Subsequently, maxillary scanned models were imported in BlueSkyPlan software and superimposed to CBCT volumes (Figure 1). The software (internationally registered as a medical device) used an algorithm to superimpose the digital model and the CBCT volume. At the end of the superimposition process, the accuracy of the superimposition was checked, by visual inspection on conventional 3 view planes (coronal, sagittal, and axial) of the correct pairing between the digital model profile (green line) and the CBCT volume (Figure 1).

When alignment was not precise, it was possible, with a reproducible time-consuming manual procedure, to achieve perfect alignment.

Outcome measurements were performed only on the patient's contralateral side to the eruption problem.

The following procedure was used to locate considered landmarks and to measure outcomes:

Landmark location was performed using the software interface with conventional 3 planes volume view (coronal, sagittal, and axial planes) and a 3D view showing superimposed maxillary digital stereolithographic model (Figure 1). The landmarks identification process started identifying the third palatal ruga and its mediolateral middle point (Figure 2). Subsequently, the coronal view plane was placed on the mediolateral middle point of the previously selected third palatal ruga (Figure 3). Three different sagittal planes were used to perform outcome evaluation at 3 different levels: the mid-palatal suture plane, 2 and 4 mm lateral to the mid-palatal suture plane (Figure 3).

In every considered sagittal plane three landmarks were identified (Figure 4) on the digital model profile (green line): third ruga point TRP, located at the intersection between digital model profile (green line) and the line representing the coronal plane passing through mediolateral middle point of the third ruga previously identified; 2 mm posteriorly to TRP (2 mmP) located on the green line of the model profile; and 2 mm anteriorly to TRP (2 mmA).

Three other analogue landmarks were identified on the sagittal plane 2 mm laterally shifted compared to the midsagittal plane: TRP/2 mmL; 2 mmP/2 mmL; 2 mmA/2 mmL (Figure 4). Finally, on the paramedian 4 mm sagittal plane, 3 other

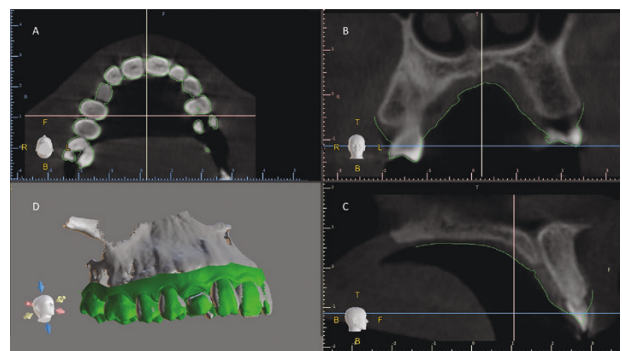


Figure 1 Software interface showing conventional view planes: axial (a); coronal (b); sagittal (c); 3D volume view with superimposed STL digital model (d).

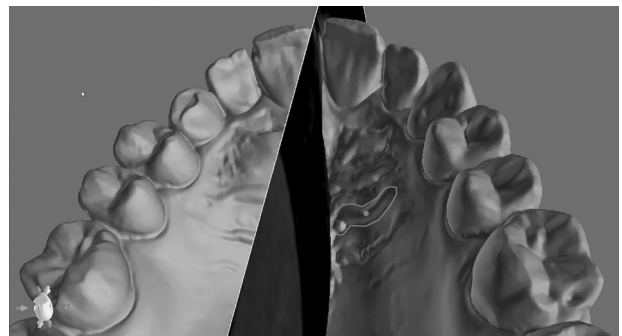


Figure 2 Third palatal ruga and its medio-lateral middle point.

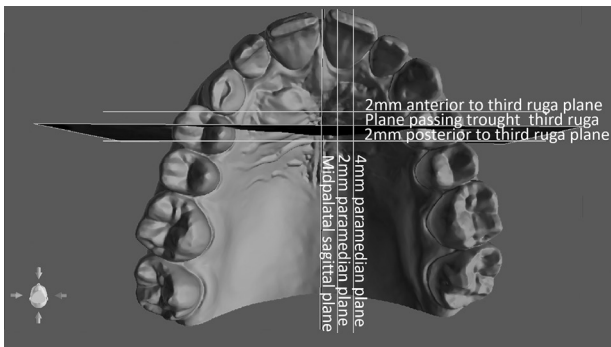


Figure 3 The coronal view plane (marked with black) was positioned on the previously located medio-lateral middle point of the third palatal ruga.

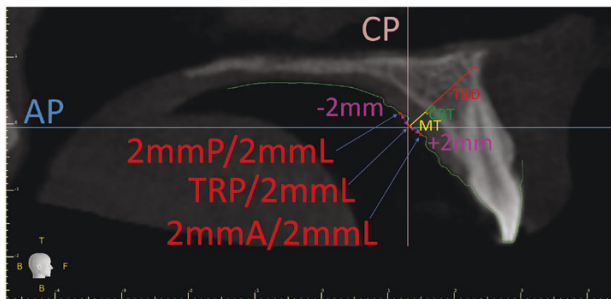


Figure 4 Sagittal plane 2 mm lateral to midpalatal suture. Coronal plane is represented as the pink line (CP). Axial Plane is represented as the blue line. 3 plane landmarks are located on the digital model profile (green line): 2 mmP (point located 2 mm posterior to the third ruga), TRP (third ruga point), and 2 mmA (point located 2 mm anterior to the third ruga). The red line perpendicular to the palatal mucosa was used to identify 3 outcomes: mucosa thickness (MT), cortical bone thickness (CBT) and total bone depth (TBD).

landmarks were localized: TRP/4 mmL; 2 mmP/4 mmL; 2 mmA/4 mmL.

For every considered landmark, a line was drawn perpendicular to the palatal mucosa and passing through it, defining the following 3 outcomes (Figure 4): mucosa thickness (MT), cortical bone thickness (CBT), and total bone depth (TBD).

Descriptive statistics and inferential statistics were performed using SPSS statistics software (version 25.0; IBM Corporation, Armonk, NY). The significance levels were set at $P < 0.05$. Preliminary data analysis included normal distribution (Shapiro-Wilk test) and equality of variances (Levene's test) evaluation. Analysis of variance (ANOVA) and Tukey post-hoc tests were used when, according to preliminary data analysis, parametric tests were needed. Similarly, Kruskal-Wallis multiple comparison test and Dunn-Bonferroni post-hoc tests were used when non-parametric tests were required.

Descriptive statistics were performed computing mean, confidence interval (95%), standard deviation, maximum and minimum values for each considered outcome.

To assess the methodological error, the digital model and CBCT superimposition, scan view identification, and outcome measurement were repeated three months apart for 10 patients randomly selected. Paired t-tests and intraclass correlation coefficients (ICCs) were used to assess the intra-operator reliability. The magnitude of the random error was assessed using the Dahlberg formula. No significant differences ($P < 0.05$) were noticed between the two readings; all measurements were reliable, with the ICC varying from 0.76 to 0.89. Random error ranged from 0.12 to 0.36 mm.

Results

Descriptive statistics of considered outcome reporting mean, 95% confidence interval, standard deviation, minimum and maximum values are reported in Tables 1–3 for mucosa thickness, cortical bone thickness, and total bone depth respectively.

Adequate total bone depth for miniscrew insertion was measured 4 mm lateral to the suture at the level of third palatal ruga (8.6 mm) and 2 mm posterior to the third palatal ruga (9.7 mm) at this level cortical bone showed around 1.3 mm of thickness and palatal mucosa thickness exhibited values around 2.8 mm.

Inferential statistics are reported in Table 4 (anteroposterior comparisons) and Table 5 (mediolateral comparisons).

Discussion

To the best of our knowledge, this is the first study that considered, as direct clinical reference, third palatal ruga to evaluate maxillary anatomical characteristics for palatal miniscrew insertion. A previous study proposed the third ruga as indirect clinical reference, performing outcomes measurements at different interdental contacts levels and comparing sagittal third ruga position to maxillary interdental contacts (5). CBCT Studies that correlate skeletal outcomes to clinical landmarks, as interdental contacts (5,6), are helpful to support clinicians during the palatal miniscrew insertion clinical procedure. Studies using as reference nasopalatine canal or other non-clinically visible anatomical structures (13, 14, 15, 16, 17, 18, 19) provide important information, but unfortunately do not support clinicians with clinical intra-operative recommendations for miniscrew placement. Third palatal ruga could be an important clinical reference, its position seems to be not affected by altered anteroposterior location of maxillary dentition (8, 10), consequently it could be a predictable reference in those malocclusions having altered sagittal teeth position.

Miniscrew insertion angle can significantly affect outcomes evaluation such as total bone depth (20). Literature showed that different published studies used different insertion angle. Some authors evaluated palatal bone depth by insertion lines perpendicular to the palatal curvature (5, 6, 20); others used lines perpendicular to constructed palatal lines oriented according to the nasopalatine canal (13, 17, 19); several authors used reference lines perpendicular to the occlusal palatal plane (15, 18, 20). Unfortunately, these methodological differences make the literature data not always directly comparable. In this investigation, it was decided to measure effective palatal bone depth on lines parallel to the sagittal plane and perpendicular to the palatal sagittal curvature (Figure 4). This miniscrew inclination is recommended in many clinical conditions (1) Moreover, this approach is supported by scientific CBCT studies evaluating different insertion angles (20), in order to maximize miniscrew bone support.

The evaluation of descriptive data showed that the maximum amount of bone depth was registered 2 mm posteriorly at the third ruga 4 mm paramedian (9.7 mm). This value was, on average, greater than the bone depth at the level of the third ruga (8.6 mm) and 2 mm anterior to the third ruga (7.3 mm). Inferential statistics showed significant differences between the insertion site 2 mm anterior to the third ruga (2 mmA/4 mmL) and 2 mm posteriorly to the third ruga (2 mmP/4 mmL) 4 mm paramedian, confirming that moving

Table 1. Descriptive statistics of total bone depth outcome, values are reported in millimetres (mm).

	Total bone depth											
	Mean +/- Confidence interval (95%)			Standard deviation			Minimum			Maximum		
	Suture	2 mmL	4 mmL	Suture	2 mmL	4 mmL	Suture	2 mmL	4 mmL	Suture	2 mmL	4 mmL
2 mmA	2.9+/-0.6	5.3+/-0.9	7.3+/-0.8	1.8	2.7	2.5	0.0	1.1	3.3	5.9	12.1	13.1
TRP	4.1+/-0.5	6.6+/-1.0	8.6+/-0.9	1.6	3.0	2.6	0.4	1.8	4.3	6.8	12.9	12.7
2 mmP	4.9+/-0.5	7.4+/-1.0	9.7+/-0.9	1.4	3.0	2.8	2.4	2.8	4.5	8.7	13.5	15.2

Table 2. Descriptive statistics of cortical bone thickness outcome, values are reported in millimetres (mm).

	Cortical bone thickness											
	Mean +/- Confidence interval (95%)			Standard deviation			Minimum			Maximum		
	Suture	2 mmL	4 mmL	Suture	2 mmL	4 mmL	Suture	2 mmL	4 mmL	Suture	2 mmL	4 mmL
2 mmA	1.1+/-0.15	0.8+/-0.16	1.3+/-0.11	0.5	0.5	0.3	0.0	0.0	0.8	2.4	1.7	2.2
TRP	1.1+/-0.12	0.9+/-0.16	1.3+/-0.08	0.4	0.5	0.3	0.4	0.0	0.9	2.1	1.7	1.9
2 mmP	1.1+/-0.12	0.9+/-0.16	1.3+/-0.10	0.4	0.5	0.3	0.6	0.0	0.7	2.2	1.6	2.3

Table 3. Descriptive statistics of mucosa thickness outcome, values are reported in millimetres (mm).

	Mucosa thickness											
	Mean +/- Confidence interval (95%)			Standard deviation			Minimum			Maximum		
	Suture	2 mmL	4 mmL	Suture	2 mmL	4 mmL	Suture	2 mmL	4 mmL	Suture	2 mmL	4 mmL
2 mmA	2.1+/-0.14	2.4+/-0.20	2.8+/-0.26	0.4	0.6	0.8	1.1	1.3	1.4	3.1	3.4	5.0
TRP	2.1+/-0.20	2.4+/-0.21	2.9+/-0.27	0.6	0.6	0.8	1.2	1.3	1.6	3.6	4.1	5.3
2 mmP	2.1+/-0.21	2.4+/-0.22	2.8+/-0.30	0.6	0.7	0.9	1.1	1.3	1.1	3.7	4.1	5.9

Table 4. Inferential statistics performed to detect any significant difference of insertion sites located at different anteroposterior levels.

	Mucosa			Cortical bone			Total bone		
	Suture	2 mmL	4 mmL	Suture	2 mmL	4 mmL	Suture	2 mmL	4 mmL
Shapiro-Wilk test	$P < .001$	$P = .068$	$P = .092$	$P < .001$	$P < .001$	$P = .008$	$P = .005$	$P = .003$	$P = .010$
Levene test	$P = .193$	$P = .917$	$P = .812$	$P = .443$	$P = .966$	$P = .665$	$P = .116$	$P = .451$	$P = .575$
Multiple comparison test	$P = .907^{**}$	$P = .946^{*}$	$P = .469^{*}$	$P = .820^{**}$	$P = .902^{**}$	$P = .870^{**}$	$P < .001^{**}$	$P = .014^{**}$	$P = .001^{**}$
Post-Hoc Tests									
2 mmA Vs TRP	NS	NS	NS	NS	NS	NS	$P = .030^{****}$	$P = .250^{****}$	$P = .870^{***}$
TRP Vs 2 mmP	NS	NS	NS	NS	NS	NS	$P = .192^{****}$	$P = .730^{****}$	$P = .184^{***}$
2 mmA Vs 2 mmP	NS	NS	NS	NS	NS	NS	$P < .001^{***}$	$P = .011^{****}$	$P < .001^{***}$

TRP (Third Ruga Point); 2 mmA (2 mm anterior to TRP); 2 mmP (2 mm posterior to TRP); 2 mmL (2 mm lateral to the suture); 4 mmL (4 mm lateral to the suture). *ANOVA Analysis of Variance, **Kruskal-Wallis multiple comparison test, ***Tukey post hoc test ****Dunn-Bonferroni post-hoc test.

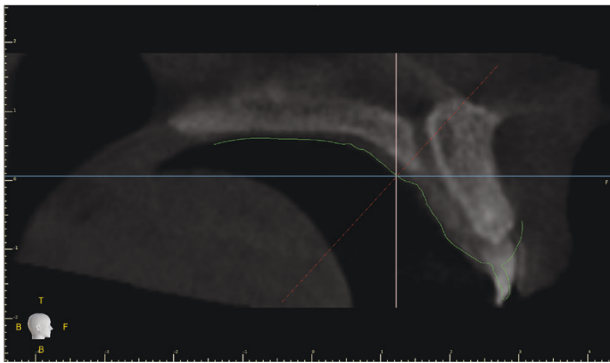
from the anterior to posterior to the third ruga there is a general increasing trend of total bone depth. However, no significant difference was noticed, in terms of total bone thickness, between the third ruga insertion site (TRP/4 mmL) and its corresponding 2 mm posterior site (2 mmP/4 mmL) 4 mm paramedian. The absence of significant difference can be explained by the anatomical variation of the anterior maxillary profile, and in particular, the anatomical relationship between the evaluating outcome axis used to measure total bone depth and the position of the anterior nasal spine (Figure 4). Visual analysis of single cases showed that when the insertion axis of

a specific insertion site (at the level of the third ruga or 2 mm posterior to TRP) was able to target the region of the anterior nasal spine maximum total bone depth was registered (Figure 4). This result could provide to the clinicians the recommendation to include, in a comprehensive maxilla assessment before palatal miniscrew insertion procedure, the evaluation of the anterior maxilla and more specifically of the anterior nasal spine. Literature unanimously reported (5, 6, 13, 14, 15, 17, 18, 19, 20) that in the distal portion of palatal process, thickness dramatically decreases moving towards distal portions of the maxilla. For this reason, this study limited bone

Table 5. Inferential statistics performed to detect any significant difference of insertion sites located at different medio-lateral levels.

	Mucosa			Cortical bone			Total bone		
	2 mmA	TRP	2 mmP	2 mmA	TRP	2 mmP	2 mmA	TRP	2 mmP
Shapiro-Wilk test	$P = .004$	$P = .001$	$P < .001$	$P = .04$	$P < .001$	$P < .001$	$P = .026$	$P = .001$	$P = .001$
Levene test	$P = .004$	$P = .120$	$P = .372$	$P = .120$	$P = .030$	$P < .001$	$P = .168$	$P < .001$	$P = .001$
Multiple comparison test	$P < .001^{**}$	$P = .001^{**}$	$P = .002^{**}$	$P < .001^{**}$	$P < .001^{**}$	$P = .002^{**}$	$P < .001^{**}$	$P < .001^{**}$	$P < .001^{**}$
Post-hoc Tests:									
Suture Vs 2 mmL	$P = .174^{****}$	$P = .253^{****}$	$P = .604^{****}$	$P = .535^{****}$	$P = .624^{****}$	$P = 1^{****}$	$P = .001^{****}$	$P < .001^{****}$	$P = .001^{****}$
2 mmL Vs 4 mmL	$P = .086^{****}$	$P = .021^{****}$	$P = .078^{****}$	$P < .001^{****}$	$P < .001^{****}$	$P = .002^{****}$	$P = .012^{****}$	$P = .014^{****}$	$P = .022^{****}$
Suture Vs 4 mmL	$P < .001^{****}$	$P < .001^{****}$	$P = .001^{****}$	$P < .029^{****}$	$P < .026^{****}$	$P = .03^{****}$	$P < .001^{****}$	$P < .001^{****}$	$P < .001^{****}$

TRP (Third Ruga Point); 2 mmA (2 mm anterior to TRP); 2 mmP (2 mm posterior to TRP); 2 mmL (2 mm lateral to the suture); 4 mmL (4 mm lateral to the suture). *ANOVA Analysis of Variance, **Kruskal-Wallis multiple comparison test, ***Tukey post hoc test ****Dunn-Bonferroni post-hoc test.

**Figure 5** Midsagittal plane passing through nasopalatine canal.

depth evaluation to 2 mm distal to TRP. The evaluation of total bone availability was also performed on different sagittal planes to evaluate total bone thickness variability at different paramedian insertion sites. Study data showed that the amount of total palatal bone significantly decreases at all considered levels moving from 4 mm lateral insertion sites to the suture insertion sites. Miniscrew insertion in the palatal median suture region was reported in the literature when palatal non-expansion treatment procedures are planned (1). This region could offer some advantages such as the presence of two cortical plates facing at the level of suture and consequently offer potential better screw stability. The analysis of descriptive data at the suture level showed a reduced amount of total bone thickness at the suture level with values (2.9, 4.1, and 4.9 mm for the 2 mmA/suture, TRP/Suture, and 2 mmP/Suture outcomes respectively) that indicate a reduction of 25 and 50%, less compared to the 2 and 4 mm paramedian insertion sites, respectively. At this level total bone availability is limited by the presence of the naso-alveolar canal (Figure 5). This finding indicates that miniscrew placement, perpendicular to palatal anterior mucosa, should be avoided in the palatal suture at the level of third ruga and immediately behind it.

In general, total bone data showed clinically significant individual variation, with standard deviation values ranging from 1.4 to 3.00, and showing outcome minimum values under the threshold values of 8 mm. This value is the minimum miniscrew length commercially available for palatal skeletal anchorage. This finding could suggest that a preliminary imaging analysis of palatal bone thickness could be mandatory before

miniscrew insertion if the clinician aims to place the miniscrew body within the palatal process of the maxillary bone.

Cortical bone thickness evaluation is an important parameter to be evaluated to choose an optimal insertion protocol. Cortical bone is the most relevant anatomical structure that opposes miniscrew penetration and at the same time determines miniscrew primary stability (21). The results of this investigation showed that the cortical bone did not change significantly its thickness in anteroposterior direction for all the considered sites. However, significant differences were found comparing cortical bone at the suture level with cortical bone 2-mm and 4-mm paramedian at all anteroposterior levels. Average values of cortical bone thickness 2 mm lateral to the suture (0.9 mm) is significantly less compared with suture ones (1.1 mm). On the contrary, cortical bone thickness 4 mm lateral to the suture (1.3 mm) is significantly thicker compared to one measured at the suture insertion sites (1.1 mm). However, the differences of cortical bone thickness are small and could be clinically not significant. Cortical bone thickness is important to estimate pre-drilling necessity before palatal miniscrew insertion. Pre-drilling could be indicated to avoid excessive insertion torque (22) and consequently reduce miniscrew failure (23). Experimental studies indicate that 1.2 mm of cortical bone thickness could cause an insertion torque value of approximately 150 N/mm (21). Clinical findings seem to show that 150 N/mm is a non-optimal value for long-term miniscrew stability (23). Considering this data pre-drilling could be not strictly indicated for the insertion palatal site, however, it could be beneficial to reach an optimal insertion torque. Moreover, pre-drilling could be potentially beneficial to improve placement accuracy during the miniscrew insertion supported by surgical dimes.

Palatal mucosa thickness is an essential outcome to select proper screw characteristics as total screw length and neck screw extension to promote optimal mucosa adaptation to miniscrew head. The evaluation of palatal mucosa thickness is not possible to execute with simple retrospective CBCT studies. When a CBCT exam is performed with tongue dorsum in contact with palatal mucosa, it is not possible to differentiate tongue dorsum from palatal mucosa and to measure mucosa thickness (24). Different methodological approach has been proposed to estimate palatal mucosa, involving different technologies such as ultrasonic measuring device (25), the use of soft tissues retractors during CBCT exam (26), bone sounding technique performed with sharp cannulas, needles or endodontic instruments (27).

Recently a new method has been validated, it was performed matching the information of CBCT data and digital models (28). In the present investigation, we applied this validated method to measure palatal mucosa thickness. The results of this study confirm previous literature findings (29), palatal mucosa increases its thickness in paramedian insertion sites, and it decreases in posterior insertion sites. Descriptive statistics showed a greater thickness at the third ruga level. Assumingly this finding was related to the greater thickness mucosa related to the presence of the third ruga. The lateral increase of palatal mucosa thickness could be also partially explained considering that paramedian evaluation planes (unlike midsagittal plane) are mediolaterally not perpendicular to the palatal mucosa. Consequently, the considered paramedian outcomes did not measure the minimum mucosa thickness values. Palatal miniscrew in this region are mainly placed parallel to the sagittal plane (1). Therefore, the mucosa outcomes were evaluated with a clinically relevant approach. Data showed that to promote an optimal palatal mucosa adaptation, 2.5 mm of miniscrew neck would be ideal for the 4 mm paramedian insertion sites and, 2 mm of neck could be an adequate choice for the 2 mm lateral insertion sites.

The limitations of this study are related to its retrospective design. Patients enrolled in the study exhibited a unilateral eruption problem. This aspect was crucial to the implementation of the study because it allowed us to retrospectively collect a sample of subjects with CBCT examination.

However, unilateral eruption problems could potentially be associated with maxillary hypoplasia. This aspect must be considered when interpreting the results of this study. To limit the influence of this potential bias, this study evaluated exclusively subjects' side with normal teeth eruption.

Conclusions

- Both third palatal ruga and 2 mm posterior to third ruga (4 mm paramedian) could be the optimal insertion site for palatal miniscrew placement, depending on individual anatomic conditions. However, total bone data showed clinically significant individual variation.
- Thickness of the cortical palatal bone showed, at 4 mm paramedian, optimal characteristics for miniscrew primary stability.
- Palatal mucosa thickness values, for the 4 mm paramedian insertion sites, suggest miniscrew neck extension of 2.5 mm for optimal mucosa adaptation.

Conflicts of interest

None to declare.

Funding

This study was financially supported by the Department of Biomedical and Dental Sciences and Morphofunctional Imaging, University of Messina, and Orthodontics Department, University of Genova.

Data Availability

The data underlying this article will be shared on reasonable request to the corresponding author.

References

1. Ludwig, B., Glasl, B., Bowman, S.J., Wilmes, B., Kinzinger, G.S. and Lisson, J.A. (2011) Anatomical guidelines for miniscrew insertion: palatal sites. *Journal of Clinical Orthodontics*, 45, 433–441; quiz 467.
2. Wilmes, B. and Drescher, D. (2008) A miniscrew system with interchangeable abutments. *Journal of Clinical Orthodontics*, 42, 574–80; quiz 595.
3. Lee, J., Miyazawa, K., Tabuchi, M., Kawaguchi, M., Shibata, M. and Goto, S. (2013) Midpalatal miniscrews and high-pull headgear for anteroposterior and vertical anchorage control: cephalometric comparisons of treatment changes. *American Journal of Orthodontics and Dentofacial Orthopedics*, 144, 238–250.
4. Kapetanović, A., Theodorou, C.I., Bergé, S.J., Schols, J.G.J.H. and Xi, T. (2021) Efficacy of Miniscrew-Assisted Rapid Palatal Expansion (MARPE) in late adolescents and adults: a systematic review and meta-analysis. *European Journal of Orthodontics*, 43, 313–323.
5. Hourfar, J., Kanavakis, G., Bister, D., Schätzle, M., Awad, L., Nienkemper, M., Goldbecher, C. and Ludwig, B. (2015) Three dimensional anatomical exploration of the anterior hard palate at the level of the third ruga for the placement of mini-implants—a cone-beam CT study. *European Journal of Orthodontics*, 37, 589–595.
6. Baumgaertel, S. (2009) Quantitative investigation of palatal bone depth and cortical bone thickness for mini-implant placement in adults. *American Journal of Orthodontics and Dentofacial Orthopedics*, 136, 104–108.
7. Bailey, L.T., Esmailnejad, A. and Almeida, M.A. (1996) Stability of the palatal rugae as landmarks for analysis of dental casts in extraction and nonextraction cases. *The Angle Orthodontist*, 66, 73–78.
8. Almeida, M.A., Phillips, C., Kula, K. and Tulloch, C. (1995) Stability of the palatal rugae as landmarks for analysis of dental casts. *The Angle Orthodontist*, 65, 43–48.
9. Christou, P. and Kiliaridis, S. (2008) Vertical growth-related changes in the positions of palatal rugae and maxillary incisors. *American Journal of Orthodontics and Dentofacial Orthopedics*, 133, 81–86.
10. Hoggan, B.R. and Sadowsky, C. (2001) The use of palatal rugae for the assessment of anteroposterior tooth movements. *American Journal of Orthodontics and Dentofacial Orthopedics*, 119, 482–488.
11. Stucki, S. and Gkantidis, N. (2020) Assessment of techniques used for superimposition of maxillary and mandibular 3D surface models to evaluate tooth movement: a systematic review. *European Journal of Orthodontics*, 42, 559–570.
12. Hourfar, J., Ludwig, B., Bister, D., Braun, A. and Kanavakis, G. (2015) The most distal palatal ruga for placement of orthodontic mini-implants. *European Journal of Orthodontics*, 37, 373–378.
13. Ryu, J.H., Park, J.H., Vu Thi Thu, T., Bayome, M., Kim, Y. and Kook, Y.A. (2012) Palatal bone thickness compared with cone-beam computed tomography in adolescents and adults for mini-implant placement. *American Journal of Orthodontics and Dentofacial Orthopedics*, 142, 207–212.
14. Chhatwani, S., Rose-Zierau, V., Haddad, B., Almuzian, M., Kirschneck, C. and Danesh, G. (2019) Three-dimensional quantitative assessment of palatal bone height for insertion of orthodontic implants—a retrospective CBCT study. *Head & Face Medicine*, 15, 9.
15. Gracco, A., Lombardo, L., Cozzani, M. and Siciliani, G. (2008) Quantitative cone-beam computed tomography evaluation of palatal bone thickness for orthodontic miniscrew placement. *American Journal of Orthodontics and Dentofacial Orthopedics*, 134, 361–369.
16. Holm, M., Jost-Brinkmann, P.G., Mah, J. and Bumann, A. (2016) Bone thickness of the anterior palate for orthodontic miniscrews. *The Angle Orthodontist*, 86, 826–831.
17. Kang, S., Lee, S.J., Ahn, S.J., Heo, M.S. and Kim, T.W. (2007) Bone thickness of the palate for orthodontic mini-implant anchorage in

- adults. *American Journal of Orthodontics and Dentofacial Orthopedics*, 131, S74–S81.
18. Nakahara, K., Matsunaga, S., Abe, S., Tamatsu, Y., Kageyama, I., Hashimoto, M. and Ide, Y. (2012) Evaluation of the palatal bone for placement of orthodontic mini-implants in Japanese adults. *Cranio: the Journal of Craniomandibular Practice*, 30, 72–79.
 19. Wang, M., Sun, Y., Yu, Y. and Ding, X. (2017) Evaluation of palatal bone thickness for insertion of orthodontic mini-implants in adults and adolescents. *The Journal of Craniofacial Surgery*, 28, 1468–1471.
 20. Becker, K., Unland, J., Wilmes, B., Tarraf, N.E. and Drescher, D. (2019) Is there an ideal insertion angle and position for orthodontic mini-implants in the anterior palate? A CBCT study in humans. *American Journal of Orthodontics and Dentofacial Orthopedics*, 156, 345–354.
 21. Wilmes, B., Rademacher, C., Olthoff, G., & Drescher, D. (2006). Parameters affecting primary stability of orthodontic mini-implants. *Journal of Orofacial Orthopedics*, 67, 162–174.
 22. Wilmes, B. and Drescher, D. (2009) Impact of insertion depth and predrilling diameter on primary stability of orthodontic mini-implants. *The Angle Orthodontist*, 79, 609–614.
 23. Motoyoshi, M., Hirabayashi, M., Uemura, M. and Shimizu, N. (2006) Recommended placement torque when tightening an orthodontic mini-implant. *Clinical Oral Implants Research*, 17, 109–114.
 24. Kim, H.J., Yun, H.S., Park, H.D., Kim, D.H. and Park, Y.C. (2006) Soft-tissue and cortical-bone thickness at orthodontic implant sites. *American Journal of Orthodontics and Dentofacial Orthopedics*, 130, 177–182.
 25. Cha, B.K., Lee, Y.H., Lee, N.K., Choi, D.S. and Baek, S.H. (2008) Soft tissue thickness for placement of an orthodontic miniscrew using an ultrasonic device. *The Angle Orthodontist*, 78, 403–408.
 26. Barriviera, M., Duarte, W.R., Januário, A.L., Faber, J. and Bezerra, A.C. (2009) A new method to assess and measure palatal masticatory mucosa by cone-beam computerized tomography. *Journal of Clinical Periodontology*, 36, 564–568.
 27. Anuradha, B.R., Shankar, B.S., John, B., Prasad, K.A., Gopinadh, A. and Devi, K.N. (2013) Assessment of palatal masticatory mucosa: a cross-sectional study. *The Journal of Contemporary Dental Practice*, 14, 536–543.
 28. Ogawa, M., et al. (2020) Accuracy of cone beam computed tomography in evaluation of palatal mucosa thickness. *Journal of Clinical Periodontology*, 47, 479–488.
 29. Poorsattar-Bejeh Mir, A., Haghanifar, S., Poorsattar-Bejeh Mir, M., & Rahmati-Kamel, M. (2017). Individual scoring and mapping of hard and soft tissues of the anterior hard palate for orthodontic miniscrew insertion. *Journal of Investigative and Clinical Dentistry*, 8, e12186.